

Local Anesthesia for Inguinal Hernia Repair Step-by-Step Procedure

Parviz K. Amid, M.D., F.A.C.S.,* Alex. G. Shulman, M.D., F.A.C.S.,†
and Irving L. Lichtenstein, M.D., F.A.C.S.†

From the Lichtenstein Hernia Institute, Harbor-UCLA Research and Education Institute, Departments of Surgery at the Harbor UCLA and Cedars-Sinai Medical Centers, and Cedars-Sinai Medical Center,† Los Angeles, California*

Objective

The authors introduce a simple six-step infiltration technique that results in satisfactory local anesthesia and prolonged postoperative analgesia, requiring a maximum of 30 to 40 mL of local anesthetic solution.

Summary Background Data

For the last 20 years, more than 12,000 groin hernia repairs have been performed under local anesthesia at the Lichtenstein Hernia Institute. Initially, field block was the mean of achieving local anesthesia. During the last 5 years, a simple infiltration technique has been used because the field block was more time consuming and required larger volume of the local anesthetic solution. Furthermore, because of the blind nature of the procedure, it did not always result in satisfactory anesthesia and, at times, accidental needle puncture of the ilioinguinal nerve resulted in prolonged postoperative pain, burning, or electric shock sensation within the field of the ilioinguinal nerve innervation.

Methods

More than 12,000 patients underwent operations in a private practice setting in general hospitals.

Results

For 2 decades, more than 12,000 adult patients with reducible groin hernias satisfactorily underwent operations under local anesthesia without complications.

Conclusions

The preferred choice of anesthesia for all reducible adult inguinal hernia repair is local. It is safe, simple, effective, and economical, without postanesthesia side effects. Furthermore, local anesthesia administered before the incision produces longer postoperative analgesia because local infiltration, theoretically, inhibits build-up of local nociceptive molecules and, therefore, there is better pain control in the postoperative period.

The preferred choice of anesthesia for all reducible adult inguinal hernia repair is local. It is safe, simple, effective, and economical, without postanesthesia side effects. Furthermore, local anesthesia administered before the incision produces longer postoperative analgesia

because local infiltration, theoretically, inhibits build-up of local nociceptive molecules and, therefore, there is better pain control in the postoperative period. Experimental studies have demonstrated that peripheral tissue injury may result in long-lasting changes in central pro-

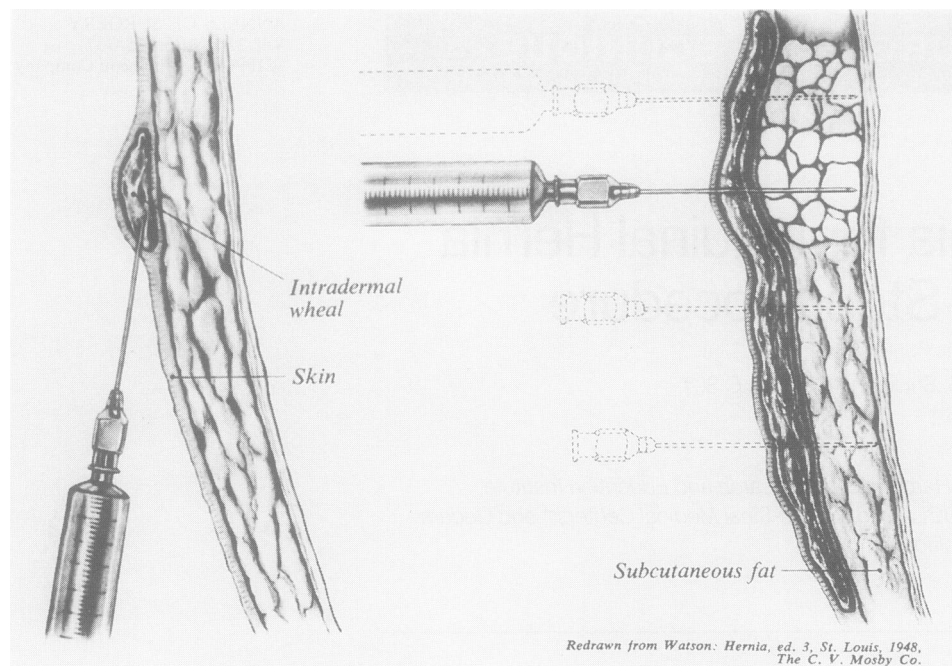


Figure 1. Making of the skin wheal and deep subcutaneous injection.

cessing, with reduction in threshold, amplification of responses, expanded receptive fields, and (after) discharges of dorsal horn neurons. Subsequently, it has been suggested that surgical trauma in humans may lead to comparable alterations, resulting in amplification and prolongation of postoperative pain.¹⁻³ Preoperative local anesthesia, in conjunction with general or spinal anesthesia, has been shown to reduce postoperative pain and wound tenderness compared with general or spinal anesthesia only.^{4,5}

MATERIALS AND METHODS

The success of local anesthesia requires a proper technique of administration and gentle manipulation of the anesthetized tissues. Several safe and effective anesthetic agents currently are available. Our choice, however, has been a 50:50 mixture of 1% lidocaine (Xylocaine, Astra Pharmaceutical Prod., Inc., Westborough, MA) and 0.5% bupivacaine (Marcaine, Sanofi Winthrop Pharmaceuticals, New York, NY). The therapeutic maximum dose of lidocaine is 300 mg in plain form, and 500 mg with epinephrine. For bupivacaine, the dose is 175 mg plain, and 225 mg with epinephrine. Such a mixture has the following advantages:

Lidocaine provides rapid onset, and bupivacaine re-

sults in a longer duration of local anesthesia. Reduction in onset time has been reported with the addition of sodium bicarbonate 1 mEq per 10 mL of lidocaine.⁶ Anesthetic duration time can be prolonged further by addition of epinephrine to the mixture. Epinephrine, however, may produce severe prolonged hypertension in patients receiving monamine oxidase inhibitors or tricyclic antidepressants.

Use of two different anesthetic agents decreases the likelihood of exceeding the therapeutic maximum dose of each individual agent. This is particularly useful in the case of simultaneous bilateral inguinal hernia repair. An average of 45 mL of this mixture usually is sufficient for a unilateral hernia operation.

The following are the different steps of the technique of local anesthesia, as currently used at our institute:

1. *Subdermic infiltration.* Approximately 5 mL of the mixture is infiltrated along the line of the incision using a 2-inch long 25-gauge needle inserted into the subdermic tissue parallel with the surface of the skin. Infiltration continues as the needle is advanced. Movement of the needle decreases the likelihood of intravascular infusion of the drugs because even if the needle penetrates a blood vessel, the tip will not remain in the vessel long enough to deliver a substantial amount of the anesthetic agent intravenously. This step blocks the subdermic nerve endings and decreases the discomfort of the

intra-dermic infiltration, which is the most uncomfortable stage of local anesthesia.

2. *Intra-dermic injection (making of the skin wheal).*

The needle previously inserted into the subdermic plane is slowly withdrawn until the tip of the needle reaches the intra-dermic level. At this point, without extracting the needle completely, the intra-dermic infiltration and making of the skin wheal is performed by very slow injection of approximately 3 mL of the mixture along the line of the incision (Fig. 1, left). Addition of sodium bicarbonate solution to increase the pH of the mixture and thereby decrease the burning pain of intra-dermic infiltration has been suggested.⁷

3. *Deep subcutaneous injection.* Ten milliliters of the mixture is injected deep into the subcutaneous adipose tissue by vertical insertions of the needle (perpendicular to the skin surface) 2 cm apart (Fig. 1, right). Again, injections are continued as the needle is kept moving to decrease the risk of intravascular infusion.

4. *Subfascial infiltration.* Approximately 8 to 10 mL of the anesthetic mixture is injected immediately underneath the aponeurosis of the external oblique through a window created in the subcutaneous adipose tissue at the lateral corner of the incision (Fig. 2). This injection floods the enclosed inguinal canal and while the rest of the subcutaneous tissue is incised, anesthetizes all three major nerves in this anatomic region. Furthermore, it separates the external oblique aponeurosis from the underlying ilioinguinal nerve, thus decreasing the likelihood of injuring the nerve when the external oblique aponeurosis is incised.

5. *Pubic tubercle and hernia sac injection.* Occasionally, infiltration of a few milliliters of the mixture at the level of the pubic tubercle, around the neck and inside the indirect hernia sac, is required to achieve complete local anesthesia. Further prolongation of the local anesthesia can be achieved by splashing 10 mL of the mixture, with the addition of epinephrine, into the inguinal canal before the closure of the external oblique aponeurosis and into the subcutaneous space before the skin closure.⁸

DISCUSSION

For 2 decades, we have used local anesthesia for more than 10,000 groin hernia repairs. Obesity has not been a problem in our experience. Even morbidly obese pa-

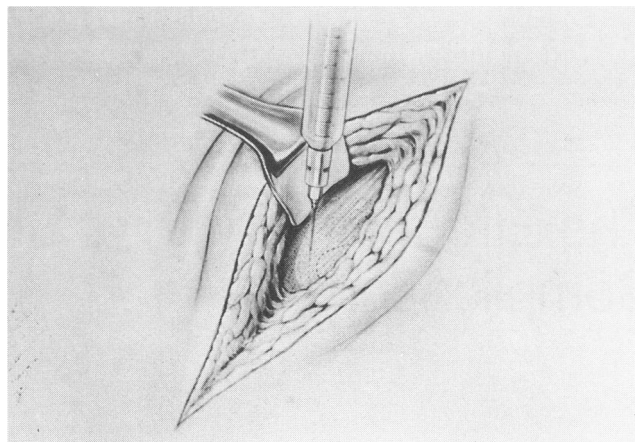


Figure 2. Subfascial infiltration.

tients do not have as much adipose tissue in the groin area as in the abdominal wall region. At times, epidural anesthesia is a preferred method for bilateral inguinal hernia repair in obese patients. Administration of sedative drugs by the surgeon, or preferably, by an anesthesiologist as “monitored anesthesia care,” for intraoperative infusion of rapid short-acting amnesic and anxiolytic agents, such as propofol, reduces the patient’s situational anxiety. Furthermore, it decreases the required amount of local anesthetic agents, especially in the case of bilateral inguinal hernia repair.

References

1. Woolf CJ. Central mechanisms of acute pain. In Bond MR, Charlton JE, Woolf CJ, eds. *Proceedings of the VIth World Congress on Pain*. Amsterdam: Elsevier, 1991, pp 25–34.
2. Dubner R. Neuronal plasticity and pain following peripheral tissue inflammation or nerve injury. In Bond MR, Charlton JE, Woolf CJ, eds. *Proceedings of the VIth World Congress on Pain*. Amsterdam: Elsevier, 1991, pp 263–276.
3. Woolf CJ. Recent advances in the pathophysiology of acute pain. *Br J Anaesth* 1989; 63:139–146.
4. Tversky M, Cozacov C, Ayache M, et al. Postoperative pain after inguinal herniorrhaphy with different types of anesthesia. *Anesth Analg* 1990; 70:29–35.
5. Buggedo GJ, Carcamo CR, Mertens RA, et al. Preoperative percutaneous ilioinguinal and iliohypogastric nerve block with 0.5% bupivacaine for post-herniorrhaphy pain management in adults. *Reg Anesth* 1990; 15:130–133.
6. Arthur GR, Covino BG. What’s new in local anesthetics. *Anesthesiology Clin North Am* 1988; 6:357.
7. Wantz, GE. *Atlas of Hernia Surgery*. New York: Raven Press, 1991, p 19.
8. Bays RA, Barry L, Vasilenko P. The use of bupivacaine in elective inguinal herniorrhaphy as a fast and safe technique for relief of postoperative pain. *Surg Gynecol Obstet* 1991; 173:433–437.